

Abdominal Tuberculosis Presenting With an Acute Abdomen in a Tertiary Care Hospital – A Case Series Study

Dr. S.Santhoshkumar¹, Dr. V. Lekshminarayani M.S.,DGO.,²,
Dr.R.Jayakumar MS.,³

¹ Postgraduate, Department Of General Surgery, Coimbatore Medical College Hospital, Coimbatore, India

² Professor, Department Of General Surgery, Coimbatore Medical College Hospital, Coimbatore, India

³ Senior Assistant Professor, Department Of General Surgery, Coimbatore Medical College Hospital, Coimbatore, India.

Abstract

Background: Abdominal tuberculosis accounts for 2% of TB cases globally. The non specific features of the disease poses diagnostic challenge which results in delay in diagnosis and development of complications. We hereby present three cases of abdominal tuberculosis that presented as acute abdomen.

Case Report: First case, a 21-year old female, presenting with abdominal pain, underwent exploratory laparotomy, right hemicolectomy with end ileostomy due to multiple ileal and caecal perforations. The second case, 15-year old female, presenting with abdominal distension and breathlessness, on evaluation diagnosed to have pulmonary and intestinal tuberculosis. The third case, 42-year old male, presenting with abdominal distension, underwent exploratory laparotomy, ileo-ileal resection anastomosis due to ileal stricture. Histopathological examination in these cases showed chronic granulomatous inflammation. Patients were diagnosed with abdominal tuberculosis and started on anti tuberculosis drugs for 6 months.

Discussion: Abdominal tuberculosis is difficult to diagnose. Diagnosis is often delayed till presented with an acute abdomen. Undiagnosed abdominal tuberculosis cases represent a notable percentage of cases who presents with acute abdomen. Imaging plays an important role in the diagnosis of abdominal tuberculosis whereas histopathological examination is gold standard for confirming diagnosis. All patients need a full course of anti tuberculosis treatment.

Key words: Tuberculosis, Abdominal tuberculosis, Acute abdomen

Date of Submission: 15-10-2020

Date of Acceptance: 31-10-2020

I. Introduction

Tuberculosis is an important cause of morbidity in developing countries mainly in India. It has become a resurgent global problem with increasing number of immunocompromised patients and the spread further aided by poverty, overcrowding and drug resistance. There is also a raise in the percentage of patients with atypical presentation and atypical extra pulmonary forms of TB. Abdominal tuberculosis poses diagnostic challenge as the non specific features of the disease which may lead to diagnostic delays and developments of complications. A high index of suspicion is important for early diagnosis. Abdominal tuberculosis involves gastrointestinal tract, mesentery, omentum, peritoneum, lymph nodes and solid viscera. Abdominal tuberculosis with an acute abdomen presents as an enormous challenge to the surgeon as radiology often fails to reveal the classical changes described in textbook. Though emergency surgery helps to overcome the crisis of acute tuberculosis abdomen permanent cure can be achieved only by ant tubercular medications. Hereby presenting such cases of tuberculosis abdomen presenting as acute abdomen.

II. Case Reports

CASE 1

A 21-year-old married female presented to our hospital's ER with generalized abdominal pain that started 5 days before. She had vomiting, diarrhoea and fever. She also reported significant loss of weight in about 2 months. On examination the patient was dehydrated, pale. Her abdomen revealed distension, generalized tenderness, guarding and rigidity, suggesting peritonitis. Her chest was clear.

Laboratory findings showed : Haemoglobin 8.7 g/dl, Hematocrit 27.2%, White blood cell count 8000/ml (PMN 91.5%), Platelets 126000/ml, Glucose 118 mg/dl, Urea 21 mg/dl, Creatinine 0.8 mg/dl, Na 143 mEq/L, K 3.9 mEq/L. Serology for HIV, HBsAg, Anti HCV are negative.

Her chest X-ray and x ray abdomen erect revealed pneumoperitoneum and features of ileus but no signs of chest disease. Ultrasonogram abdomen and pelvis was reported as pneumoperitoneum with free fluid in peritoneal cavity.

Under the diagnosis of peritonitis the patient was resuscitated and taken for emergency laparotomy.

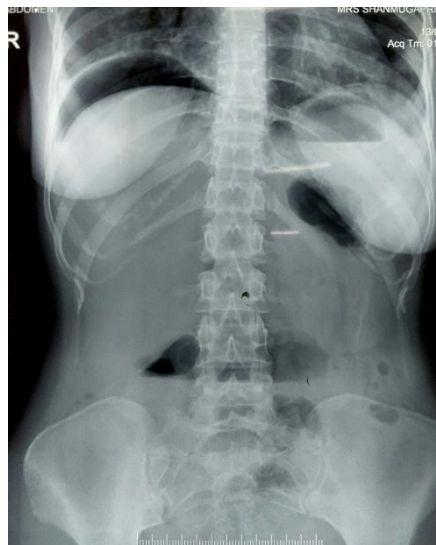

FIG 1. X RAY ABDOMEN – AIR UNDER DIAPHRAGM WITH ILEUS

The findings are thickening of mesentery with multiple nodules of varying sizes with largest measuring 3cm, nodules over terminal ileum, ileocaecal junction and caecum with multiple ileal and caecal perforations. Rest of the bowel and solid organs were normal.

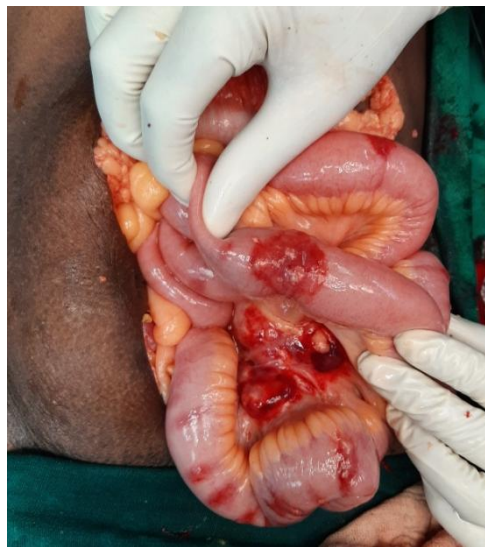


FIG 2. INTRA OP FINDING – MULTIPLE ILEAL PERFORATION WITH MESENTERY NODULES

Right hemicolectomy with end ileostomy was done. Specimen sent for histopathological examination. Histopathology revealed caseating granulomas with langhan’s giant cells.

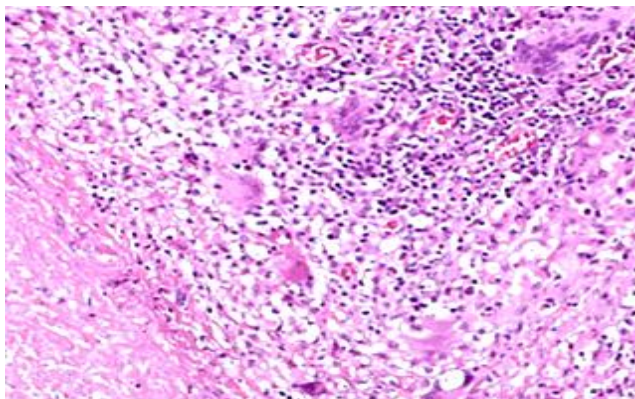


FIG 3. HISTOPATHOLOGY - CASEATING GRANULOMAS

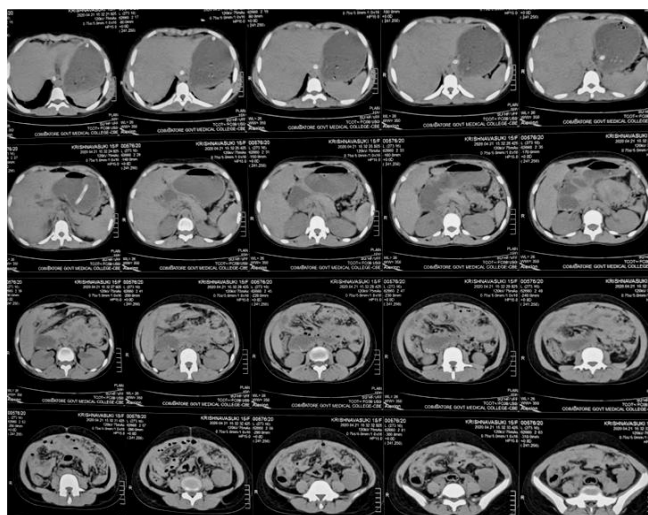
Diagnosis of tuberculosis was made. Antituberculosis regimen was started. The patient had uneventful postoperative course and was discharged after 10 days.

CASE 2

A 15-year-old female presented to ER with bilious vomiting, abdominal distension for 3 days. She also complained of fever and cough with breathlessness for a week. On examination the patient was anaemic with dyspnea. Her chest showed reduced air entry in left hemithorax. Her abdomen revealed distension, mild tenderness, with no signs of guarding and rigidity.

Laboratory findings showed : Haemoglobin 9 g/dl, White blood cell count 12300/ml, Glucose 97 mg/dl, Urea 35 mg/dl, Creatinine 1.1 mg/dl, Na 134 mEq/L, K 3.3 mEq/L. Viral markers were negative.

Her chest X-ray showed moderate left pleural effusion. X ray abdomen erect revealed dilated small bowel loops with multiple air fluid levels. Ultrasonogram abdomen and pelvis was reported as moderate free fluid in peritoneal cavity with internal septations and multiple levels of bowel wall thickening with omental and mesenteric fat stranding. CT Chest showed moderate left pleural effusion with thickened pleura. CECT abdomen pelvis revealed multifocal areas of small bowel thickening along jejuna and ileal loops with mesenteric and omental fat stranding with multiple enlarged mesenteric lymph nodes and para aortic nodes. Features suggesting tuberculosis abdomen with sub acute intestinal obstruction.



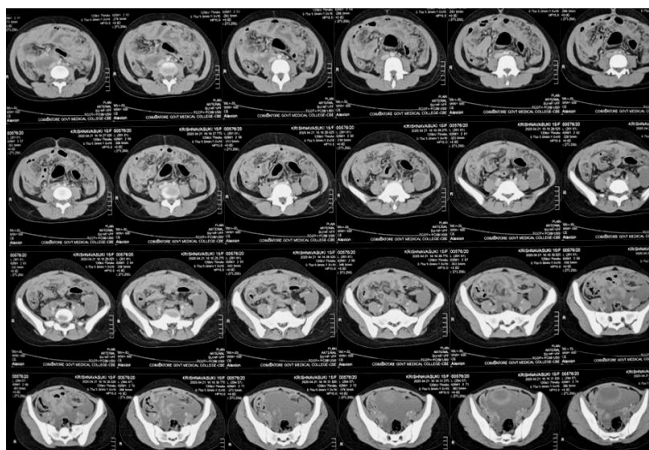


FIG 4 & 5. CECT ABDOMEN & PELVIS – FEATURES OF TUBERCULOUS ABDOMEN

Left intercostal drainage done. Fluid analysis for CB NAAT showed positive for Mycobacterium tubercle bacilli. A diagnosis of Pulmonary and intestinal tuberculosis with sub acute intestinal obstruction was made. Patient started on ATD and conservative management for sub acute intestinal obstruction. Patient had uneventful course.

CASE 3

A 42-year-old male presented with vomiting, abdominal distension and fever for 3 days. On examination the patient was dehydrated. His chest was clear. His abdomen revealed distension, diffuse tenderness and voluntary guarding

His chest X-ray was features of chronic obstructive pulmonary disease. X ray abdomen erect revealed dilated small bowel loops with multiple air fluid levels. Ultrasonogram abdomen and pelvis showed moderate free fluid and dilated bowel loops with features of intestinal obstruction. CECT abdomen pelvis revealed dilated small bowel (jejunum and ileum) with collapsed distal bowel loops with ileal stricture / adhesions.

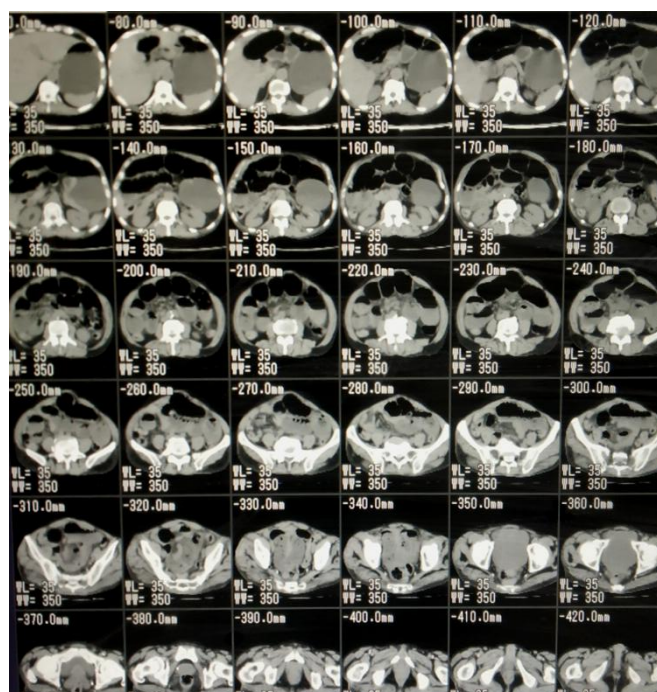


FIG 6. CECT ABDOMEN & PELVIS – FEATURES OF INTESTINAL OBSTRUCTION WITH ILEAL STRICTURE

Patient underwent emergency laparotomy. The findings were ileal stricture. Ileal resection and anastomosis was done.

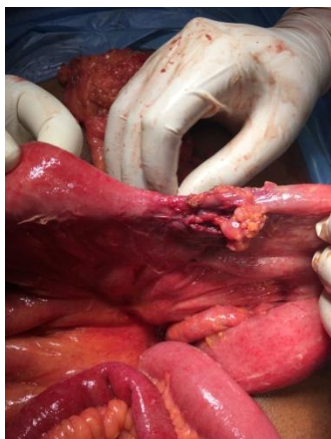

FIG 7. INTRA OP FINDING – ILEAL STRICTURE

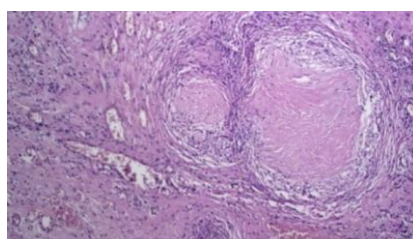


FIG 8. HISTOPATHOLOGY - CASEATING GRANULOMAS

Histopathological examination of the specimen showed caseating necrosis with langhan's giant cells and chronic inflammatory cell infiltrate. Antituberculosis regimen was started. The patient had uneventful postoperative course and was discharged after 10 days.

III. Discussion

Tuberculosis is a life threatening disease which can affect any organ. India has the world's largest tuberculosis cases which is about 26 % of world TB cases. The primary site of TB is lung from where it gets disseminated. The diagnosis of extra pulmonary TB can be difficult as it presents with non specific clinical and radiological features and requires high degree of suspicion. The abdominal tuberculosis, though not common can cause significant morbidity and mortality. Approximately 15-25 % of abdominal TB has concomitant pulmonary TB. Abdominal TB occurs in four forms: tuberculous lymphadenopathy, peritoneal tuberculosis, gastrointestinal tuberculosis and visceral tuberculosis involving viscera's. More often, a combination of these findings occur in any individual patient.

Modes of involvement includes ingestion of infected food or milk, infected sputum, haematogenous spread, contagious spread from adjacent foci and rare through lymphatics.

The small bowel and the ileocaecal region are the most common site of TB involvement. Relatively longer fecal stasis, neutral pH, high density of lymphoid tissues and absorption mechanisms make ileocaecal region predilection of ileocaecal region. Isolated colon involvement remains the next most common site. The most common pathology is intestinal stricture with or without perforation.

The manifestation of the disease is divided into three categories: ulcerative form (60%), seen in those with poor immune response; hypertrophic form (10%), occurs in those with enhanced immune response; ulcero-hypertrophic (30%) presenting as mass that leads to misdiagnosis as malignancy. On basis of study by Tripathi et al., patients most commonly presented with abdominal pain, fever, weight loss regardless of the anatomical involvement.

The diagnosis of abdominal tuberculosis is usually done by radiological and histopathological studies. Computed tomography (CT) remains imaging modality of choice for assessing and diagnosis abdominal TB. Biopsy methods include endoscopy guided GI mucosal biopsy; image guided percutaneous biopsy, and endoscopic ultrasound guided biopsy, open / laparoscopic surgery biopsy. Caseating necrotic granulomas with langhans giant cells is the histological hallmark of TB. Ascitic fluid analysis shows protein >3g / dL, leucocytosis (150-4000/microlitre) predominantly of lymphocytes. Serum Adenosine Deaminase (ADA) levels > 54 U / L, ascitic fluid ADA > 36 U / L, ascitic fluid to serum ADA ratio more than 0.98 are suggestive of tuberculosis. Sharma et al. studied 70 cases of abdominal tuberculosis and found evidence of active or cured lesions in chest X-ray in 22 cases (46%). Among radiological studies, ultrasonogram remains initial modality of choice. Barium studies are still gold standard for demonstrating strictures, fistulas. Contrast enhanced CT and

CT enterography provide adequate cross sectional imaging for assessing the disease. Recently, molecular and immunological studies are used for rapid diagnosis of abdominal TB. The insertion sequence IS6110 is used as a target sequence for polymerase chain reaction. Multiplex PCR using MPB64 and IS6110 are useful in rapid diagnosis of gastrointestinal TB. However, uncommon availability of PCR utilization is the notable drawback, notably on developing countries such as India.

Abdominal TB is generally responsive to medical management if diagnosed early. Surgery is usually reserved for cases presenting as acute abdomen such as non resolving intestinal obstruction, perforation, and abscess or fistula formation. Endoscopy guided balloon dilatation is an alternative for surgery in GI strictures.

Diagnosed cases of abdominal TB are treated with 6 months course of Anti tubercular drugs.

The surgeries commonly performed in abdominal TB are conservative surgery like strictureplasty, radical surgeries like right hemicolectomy providing complete eradication of disease and bypass surgery like enteroenterostomy. Steroids may be added to prevent adhesions.

IV. Conclusion

Abdominal tuberculosis constitutes a significant proportion of acute abdomen cases attending the emergency. Requires a high degree of suspicion to make diagnosis of TB abdomen. The most common pathology is intestinal stricture with or without perforation. All most all patients need surgical intervention. Surgical exploration, intensive post operative care, and ant tubercular regimen helps to attain complete cure of the disease.

CONFLICTS OF INTEREST

There is no conflict of interest.

References:

- [1]. E.H. Choi, W.J. Coyle, Gastrointestinal tuberculosis, *Microbiol. Spectr.* 4 (6) (2016)
- [2]. U. Debi, et al., Abdominal tuberculosis of the gastrointestinal tract: revisited, *World J. Gastroenterol.* 20 (40) (2014) 14831–14840
- [3]. V.H. Chong, K.S. Lim, Gastrointestinal tuberculosis, *Singap. Med. J.* 50 (6) (2009) 638–645, quiz 646. PMID: 19551320.
- [4]. P.B. Tripathi, A.D. Amarapurkar, Morphological spectrum of gastrointestinal tuberculosis, *Trop. Gastroenterol.* 30 (1) (2009) 35–39. PMID: 19624086
- [5]. Rosado E, Penha D, Paixao P, Costa AMD, Amadora PT. Abdominal tuberculosis - Imaging findings. Educational exhibit; ECR 2013: C-0549 [DOI: 10.1594/ecr2013/C-0549]
- [6]. World Health Organization. Global tuberculosis report 2013. Geneva: WHO. 23 Oct 2013. Available from: URL:http://apps.who.int/iris/bitstream/10665/91355/1/9789241564656_eng.pdf
- [7]. Akhan O, Pringot J. Imaging of abdominal tuberculosis. *Eur Radiol* 2002; 12: 312-323 [PMID: 11870428]
- [8]. Marshall JB. Tuberculosis of the gastrointestinal tract and peritoneum. *Am J Gastroenterol* 1993; 88: 989-999 [PMID: 8317433]
- [9]. Chavhan GE, Ramakantan R. Duodenal tuberculosis: radiological features on barium studies and their clinical correlation in 28 cases. *J Postgrad Med* 2003; 49: 214-217 [PMID:14597783]
- [10]. Jain R, Sawhney S, Bhargava DK, Berry M. Diagnosis of abdominal tuberculosis: Sonographic findings in patients with early disease. *AJR* 1995; 165: 1391-1395.
- [11]. Bhansali SK. Abdominal tuberculosis: experiences with 300 case. *Am J Gastroenterol* 1997; 67: 324-337.
- [12]. Akinoglu A, Bilgin I. Tuberculous enteritis and peritonitis. *Can J Surg* 1988; 31: 55-58.
- [13]. Bouma BJ, Tytgat KM, Schipper HG, Kager PA. Be aware of abdominal tuberculosis. *Neth J Med* 1997; 51: 119-122.
- [14]. Kapoor VK. Modern Management of Abdominal Tuberculosis. In: Taylor I and Johnson CD (Eds) *Recent Advances of Surgery*. 35 th vol.2013;pp156-69.
- [15]. Sircar S, Taneja VA. Epidemiology and Clinical Presentation of Abdominal Tuberculosis-a retrospective study. *J. Indian Medical Association.* 1996; 94 (9): 342-44.
- [16]. Sharma M P and Bhatia V. Abdominal Tuberculosis. *Indian Journal of Medical Research.* 2004;120:305-15.
- [17]. Kumar R, Saddique M,Iqbal P, Khan NA. Abdominal Tuberculosis-Clinical Presentation and Outcome. *Pakistan Journal of Surgery.* 2007; 23(4):242-44.
- [18]. Wadhwa N, Agarwal S, Mishra K. Reappraisal of Abdominal Tuberculosis. *J. Ind Med Assoc.* 2004;102(1):31-2.
- [19].